

# Mutation in *PQBP1* Is Associated With Periventricular Heterotopia

Volney L. Sheen,<sup>1</sup> Alcy R. Torres,<sup>2</sup> Xiang Du,<sup>1</sup> Brenda Barry,<sup>1,3</sup> Christopher A. Walsh,<sup>1,3</sup> and Virginia E. Kimonis<sup>4\*</sup>

<sup>1</sup>Department of Neurology, Beth Israel Deaconess Medical Center, Harvard Medical School, Boston, Massachusetts

<sup>2</sup>Department of Pediatrics, Child Neurology, The Children's Hospital, Boston, Massachusetts

<sup>3</sup>Howard Hughes Medical Institute, Boston, Massachusetts

<sup>4</sup>Department of Pediatrics, Division of Genetics, University of California at Irvine School of Medicine, Irvine, California

Received 22 December 2009; Accepted 7 April 2010

## TO THE EDITOR:

Periventricular heterotopia (PH) is characterized by the ectopic presence of neuronal nodules lining the lateral ventricles. Most genetic causes of PH are due to mutations in the X-linked *filaminA* (*FLNA*) gene [Fox et al., 1998]. Mutations in *FLNA* can also cause an otopalatodigital (OPD) spectrum disorder in the absence of PH [Robertson et al., 2003]. The OPD spectrum results in hearing loss, craniofacial dysmorphism (hypertelorism, prominent supraorbital ridges, ear abnormalities, broad nasal bridge, small mouth, down-slanted palpebral fissures and cleft palate) and skeletal abnormalities leading to shortened digits and short stature. We report on a similar phenotype of PH with associated features of OPD, due to a mutation in the *polyglutamine tract binding protein 1* gene (*PQBP1*) on Xp11.

The 20-year-old male proband was followed in the neurogenetics clinic given his early history of developmental delay and mental retardation (Fig. 1). He had microcephaly (HC = 55 cm, 25th centile) and short stature (height = 164.3 cm, weight 54.3 kg, both below the 5th centile). He exhibited dysmorphic craniofacial features including a broadened nose with narrow chin, freckled tongue, and low-set, cupped ears. Examination of the chest, heart, spine, genitalia, and extremities showed no gross abnormalities except for flat feet. General neurological evaluation demonstrated impaired hearing and mild cognitive impairment with difficulty reading and forgetfulness with staring spells. Further workup for a chronic cough and respiratory issues revealed numerous sub-centimeter pulmonary nodules on chest computed tomography. Exercise oximetry was normal. Histoplasmosis and coccidiomycosis titers, anti-neutrophil cytoplasmic antibody and angiotensin converting enzyme levels were unremarkable. In preparation for bronchoscopy, the patient had an elevated partial thromboplastin time (39.5), normal prothrombin time, negative lupus anticoagulant, and low-level positive anticardiolipin antibody. Factor XI was low (22%), with normal VIII and IX. Genetic evaluation excluded a peroxisomal disorder. Lactate, pyruvate, acyl carnitine, acyl glycine

## How to Cite this Article:

Sheen VL, Torres AR, Du X, Barry B, Walsh CA, Kimonis VE. 2010. Mutation in *PQBP1* is associated with periventricular heterotopia. *Am J Med Genet Part A* 9999:1–3.

studies were normal. No mitochondrial mutations were detected. EEG showed no electrographic correlate to the staring episodes. MR imaging demonstrated nodular gray matter heterotopia along the trigones of the lateral ventricles.

The 23-year-old affected brother shared features similar to his sibling, including mental retardation, microcephaly, dysmorphic facies, hearing loss and short stature. In addition, he had a cleft palate, fourth finger camptodactyly, broad distal phalanges of the thumbs and toes, and a curved penis. The mother had a past medical history notable for sarcoidosis, diabetes, hypertension and an aortic aneurysm. MRI of the brain for both sibling and mother did not show PH.

The affected males and carrier mother were found to harbor an AGAG deletion at nucleotide 459–462 in exon four of the *PQBP1* gene. The resultant frameshift predicts early protein truncation, leading to a partially functional proline rich domain and complete absence of the nuclear localization signal and the cell membrane targeting C2 domains in *PQBP1*. Sequencing of the *FLNA* gene in this patient identified no exonic mutations. The mother had

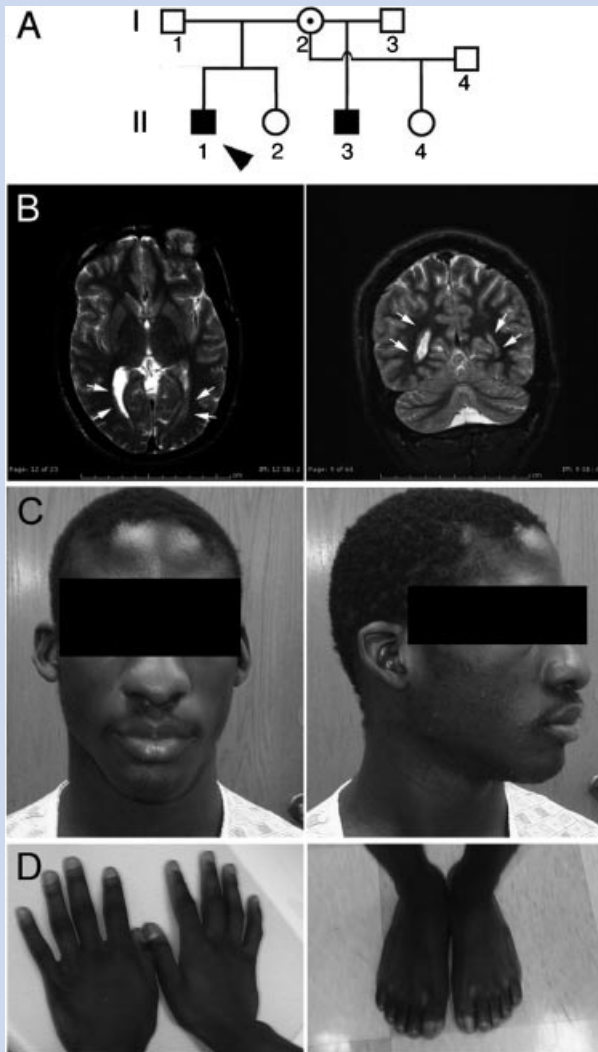
Volney L. Sheen and Alcy R. Torres contributed equally to this work.

\*Correspondence to:

Virginia E. Kimonis, M.D., UC Irvine Medical Center, 101 The City Drive, ZC 4482, Orange, CA 92868. E-mail: vkimonis@uci.edu

Published online 00 Month 2010 in Wiley Online Library (wileyonlinelibrary.com).

DOI 10.1002/ajmg.a.33507



**FIG. 1.** Features of periventricular heterotopia (PH) and otopalatodigital spectrum disorder (OPD) due to mutations in the the polyglutamine tract binding protein 1 gene (*PQBPI*). **A:** Schematic of pedigree. Black squares = affected males, arrowhead = proband with PH, circle with dot = obligate female carrier. **B:** Axial and coronal MR images of proband II-1 demonstrate bilateral PH (arrows) along the trigones of the lateral ventricles. **C:** Photomicrographs of proband show the broad nose and low-set, cupped ears consistent with OPD. **D:** Photomicrographs of proband show flat feet and slightly broad distal phalanges.

random X-inactivation studies. Sequencing of the *PQBPI* gene in an additional 41 sporadic cases of PH failed to demonstrate any mutations. (The research studies were prospectively reviewed and approved by the IRB at Children's Hospital Boston and the Beth Israel Deaconess Medical Center.)

Hearing loss, craniofacial features, and short stature with flattened fingers were consistent with an OPD spectrum disorder. The presence of PH in one male and X-linked inheritance pattern further raised the possibility that *FLNA* might be the causal gene

in this pedigree. Screening from a nonsyndromic X-linked mental retardation panel (14 genes in total, City of Hope), however, demonstrated that this same phenotype can be associated with mutations in *PQBPI*. Significant overlapping features between *PQBPI* mutations and OPD/PH suggest that the causal genes share similar functions.

Mutations in *PQBPI* (including the same deletion observed here) have been reported to cause Renpenning syndrome (RS) [Kalscheuer et al., 2003]. RS is characterized by mental retardation and microcephaly, lean body habitus, facial dysmorphism (including broad nasal bridge, cupped ears, and triangular face) and short stature; each of these features is present in the current patient. Other more variable features reported with RS, including small testes and midline defects such as anal atresia or imperforate a.u., iris coloboma and tetralogy of Fallot [Kleefstra et al., 2004], were not observed in this family. Finally, this is the first patient of African American descent, as all prior mutations for *PQBPI* gene have been reported in Caucasian families.

Aside from cognitive impairment, neurological manifestations in RS are not common and no prior reports have documented PH formation. Seizures, spasticity, blindness, and hearing loss have been reported [Stevenson et al., 2005]. Brain imaging with computerized tomography has been described in several males but was either normal or only showed microcephaly, mild dilation of the lateral ventricles secondary to brain atrophy, calcification of the globus pallidus and periventricular frontal white matter. PH, however, can often be missed on computerized tomography and thus may not have been identified on initial characterization.

Genes associated with PH (*FLNA*, *ARFGEF2*, *Mekk4*, *Napa*) regulate vesicle trafficking [Pang et al., 2008]. *FLNA* directs the internalization of cell surface receptors. *ARFGEF2* assists in assembly of coat proteins necessary for vesicle transport. In mice, *mekk4* regulates FlnA expression, while *Napa* is required for vesicle fusion. Similarly, perturbations in vesicle transport are thought to contribute to the pathology of polyglutamine repeat diseases.

Recent studies have shown that individuals with mutations in the *LRP2* gene, like those with *PQBPI* mutations, variably develop PH [Kantarci et al., 2007]. That some affected individuals show heterotopia while others do not, suggests involvement of a stochastic process in causing this malformation. Alternatively, the single affected individual in this report may be due to some other unidentified genetic cause or external environmental insult.

Collectively, these observations suggest that variable loss of cell adhesion from impaired vesicle trafficking disrupts the neuroepithelial lining or neuronal migration and underlies PH formation.

## ACKNOWLEDGMENTS

This work was supported by grants to VLS from R21HD054347 and R01NS063997 and CAW from R37N335129. VLS is a Beckman Young Investigator and Doris Duke Clinical Scientist Development Award Recipient. C. A. Walsh is an Investigator of the Howard Hughes Medical Institute. This research was in part supported by a grant from the Massachusetts' Alzheimer's Disease Research Center and the Harvard NeuroDiscovery Center.

## REFERENCES

- Fox JW, Lamperti ED, Ekioglu YZ, Hong SE, Feng Y, Graham DA, Scheffer IE, Dobyns WB, Hirsch BA, Radtke RA, Berkovic SF, Huttenlocher PR, Walsh CA. 1998. Mutations in filamin 1 prevent migration of cerebral cortical neurons in human periventricular heterotopia. *Neuron* 21:1315–1325.
- Kalscheuer VM, Freude K, Musante L, Jensen LR, Yntema HG, Gécz J, Sefiani A, Hoffmann K, Moser B, Haas S, Gurok U, Haesler S, Aranda B, Nshedjan A, Tzschach A, Hartmann N, Roloff TC, Shoichet S, Hagens O, Tao J, Van Bokhoven H, Turner G, Chelly J, Moraine C, Fryns JP, Nuber U, Hoeltzenbein M, Scharff C, Scherthan H, Lenzner S, Hamel BC, Schweiger S, Ropers HH. 2003. Mutations in the polyglutamine binding protein 1 gene cause X-linked mental retardation. *Nat Genet* 35:313–315.
- Kantarci S, Al-Gazali L, Hill RS, Donnai D, Black GC, Bieth E, Chassaing N, Lacombe D, Devriendt K, Teebi A, Loscertales M, Robson C, Liu T, MacLaughlin DT, Noonan KM, Russell MK, Walsh CA, Donahoe PK, Pober BR. 2007. Mutations in LRP2, which encodes the multiligand receptor megalin, cause Donnai-Barrow and facio-oculo-acoustico-renal syndromes. *Nat Genet* 39:957–959.
- Kleefstra T, Franken CE, Arens YH, Ramakers GJ, Yntema HG, Sistermans EA, Hulsmans CF, Nillesen WN, van Bokhoven H, de Vries BB, Hamel BC. 2004. Genotype–phenotype studies in three families with mutations in the polyglutamine-binding protein 1 gene (PQBP1). *Clin Genet* 66:318–326.
- Pang TA, Atefy R, Sheen V. 2008. Malformations of cortical development. *Neurologist* 14:181–191.
- Robertson SP, Twigg SR, Sutherland-Smith AJ, Biancalana V, Gorlin RJ, Horn D, Kenwick SJ, Kim CA, Morava E, Newbury-Ecob R, Orstavik KH, Quarrell OW, Schwartz CE, Shears DJ, Suri M, Kendrick-Jones J, Wilkie AO, OPD-spectrum Disorders Clinical Collaborative Group. 2003. Localized mutations in the gene encoding the cytoskeletal protein filamin A cause diverse malformations in humans. *Nat Genet* 33:487–491.
- Stevenson RE, Bennett CW, Abidi F, Kleefstra T, Porteous M, Simensen RJ, Lubs HA, Hamel BC, Schwartz CE. 2005. Renpenning syndrome comes into focus. *Am J Med Genet Part A* 134A:415–421.