

Phenotypic Heterogeneity in Woodhouse–Sakati Syndrome: Two New Families With a Mutation in the *C2orf37* Gene

Tawfeg Ben-Omran,^{1,2*} Rehab Ali,¹ Mariam Almureikhi,¹ Seham Alameer,³ Muna Al-Saffar,⁴ Christopher A. Walsh,^{4,5} Jillian M. Felie,⁴ and Ahmad Teebi^{1,2}

¹Section of Clinical and Metabolic Genetics, Department of Pediatrics, Hamad Medical Corporation, Doha, Qatar

²Departments of Pediatrics and Genetic Medicine, Weil-Cornell Medical College, New York and Doha, Qatar

³Department of Pediatrics, King Khalid National Guard Hospital, Jeddah, K.S.A, Qatar

⁴Division of Genetics, Manton Center for Orphan Disease Research and Howard Hughes Medical Institute, Department of Medicine, Children's Hospital Boston, Boston, Massachusetts

⁵Departments of Pediatrics and Neurology, Harvard Medical School, Boston, Massachusetts

Received 10 October 2010; Accepted 27 June 2011

Hypogonadism, alopecia, diabetes mellitus, mental retardation, and extrapyramidal syndrome [also known as Woodhouse–Sakati syndrome (WSS)] is a rare autosomal recessive neuroendocrine and ectodermal disorder. The syndrome was first described by Woodhouse and Sakati in 1983, and 47 patients from 23 families have been reported so far. We report on an additional seven patients (four males and three females) from two highly consanguineous Arab families from Qatar, presenting with a milder phenotype of WSS. These patients show the spectrum of clinical features previously found in WSS, but lack evidence of diabetes mellitus and extrapyramidal symptoms. These two new families further illustrate the natural course and the interfamilial phenotypic variability of WSS that may lead to challenges in making the diagnosis. In addition, our study suggests that WSS may not be as infrequent in the Arab world as previously thought. © 2011 Wiley Periodicals, Inc.

Key words: Arab; Woodhouse–Sakati syndrome; hypogonadism; alopecia; deafness; diabetes mellitus; learning disabilities; Qatar; autosomal recessive

INTRODUCTION

Woodhouse–Sakati syndrome (WSS) (OMIM# 241080) is a rare autosomal recessive disorder, with about 47 patients reported in the literature [Woodhouse and Sakati, 1983; Devriendt et al., 1996; Gül et al., 2000; Al-Semari and Bohlega, 2007; Medica et al., 2007; Koshy et al., 2008; Schneider and Bhatia, 2008; Alazami et al., 2010; Rachmiel et al., 2011]. The cardinal features include alopecia, hypogonadism, diabetes mellitus, mental retardation, sensorineural hearing loss, and extrapyramidal signs. Additional manifestations such as seizures, white matter abnormalities of the brain, polyneuropathy, thyroid dysfunction, keratoconus, and syndactyly of the hands or feet have been described in some cases. Recently, it

How to Cite this Article:

Ben-Omran T, Ali R, Almureikhi M, Alameer S, Al-Saffar M, Walsh CA, Felie JM, Teebi A. 2011. Phenotypic heterogeneity in Woodhouse–Sakati syndrome: Two new families with a mutation in the *C2orf37* gene. *Am J Med Genet Part A* 155:2647–2653.

has been shown that mutations in the *C2orf37* gene cause WSS [Alazami et al., 2008]. Herein, we report seven patients from two families belonging to a highly consanguineous Bedouin Qatari tribe that have a mild phenotype of WSS and mutations in the *C2orf37* gene.

CLINICAL REPORTS

Seven patients with WSS are described from two families of a consanguineous inbred Bedouin tribe.

Family 1

The parents are healthy first cousins and have one affected son, two affected daughters, and seven phenotypically normal children. Figure 1 illustrates the family pedigree, and see Table I for a synopsis

*Correspondence to:

Tawfeg Ben-Omran, M.D., F.R.C.P.C., F.C.C.M.G., Department of Pediatrics, Hamad Medical Corporation, P.O. Box 3050, Doha, Qatar.

E-mail: tawben11@hotmail.com

Published online 30 September 2011 in Wiley Online Library (wileyonlinelibrary.com).

DOI 10.1002/ajmg.a.34219

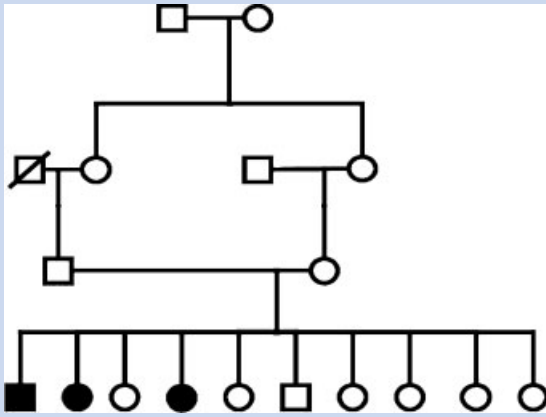


FIG. 1. Pedigree of family 1 (Patients 1–3).

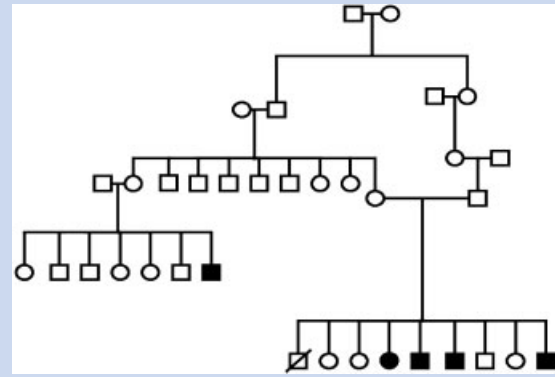


FIG. 2. Pedigree of family 2 (Patients 4–7).

of the symptoms. For a summary of the laboratory findings, see Table III.

Patient 1 is a 23-year-old male (Fig. 3) who had an unremarkable perinatal and developmental history. He presented at the age of 16 years because of delayed puberty. Endocrine evaluation revealed that he had a low testosterone level of 1.48 nmol/L (reference range is 10.4–35) and so he was treated with testosterone injections every 3 months with no significant improvement. At the age of 20 years, he was found to have myopia and moderate sensorineural hearing loss. The family reported partial frontal alopecia since early childhood. Patient 1 is not attending school due to learning disabilities and poor school performance. He has an IQ of 75, suggesting borderline intellectual disability. On examination, his weight and head circumference were at the 5th centile, and his height was at the 50th centile. He had a long face, frontal alopecia, and sparse eyebrows. He had no facial, axillary or pubic hair and his Tanner stage was two. Patient 1 exhibited no involuntary movements. His bone age was delayed by 3 years, and there was no scoliosis. Hormonal studies revealed a low IGF-1 level of 117 ng/ml (reference range: 187.9–400) and an HbA1C of 5.9 (reference range: 4.8–6). Other tests that showed results within normal limits included liver and thyroid function tests, lipid profile, testosterone, prolactin, and growth hormone levels, glucose tolerance test and insulin levels. Scrotum ultrasound showed normal sized testes (right testis: 3.9 × 1.2 cm, left testis: 3.3 × 1.4 cm) and a mild left-sided varicocele. Finally, a brain MRI, including the pituitary gland, was also unremarkable.

Patient 2 is a 20-year-old female who presented at the age of 16 years with delayed puberty and primary amenorrhea and was reported to have had frontal alopecia since early childhood. Both antenatal and perinatal histories were normal, and her early development was said to be unremarkable. At the time of presentation, she was seen by an endocrinologist who started her on hormone replacement therapy, after which her menses began but no significant improvement in secondary sexual characteristics was noted. At 19 years of age, she was seen by an ophthalmologist for poor vision and was found to have bilateral keratoconus. A hearing

assessment revealed bilateral mild sensorineural deafness. She had no involuntary movements. Currently, Patient 2 is exhibiting some learning disabilities and poor school performance. She has borderline intellectual disability with an IQ of 78. On physical examination, her weight and height were at the 5th centile and she was noted to have a long face with frontal alopecia as well as long fingers. Tanner stage was 2; she had minimal breast budding and minimal axillary and pubic hair. Bone age was delayed by 3 years and there was no scoliosis. Hormone studies showed normal growth hormone, prolactin, cortisol, LH, FSH, TSH, and T4 levels. Estradiol level was found at <37 pmol/L (reference range: Follicular: 88–418, Mid Cycle: 228–1960, Luteal: 294–1102), which has since normalized as she is on hormonal therapy. Her HbA1C was normal at 5.9 (reference range: 4.8–6), and IGF-1 was low at 39.5 ng/ml (reference range: 187.9–400). Patient 2 had a normal glucose tolerance test. A pelvic MRI showed a hypoplastic uterus and non-visualized ovaries. Her brain MRI was unremarkable.

Patient 3 is a 17-year-old female who presented with primary amenorrhea and delayed puberty. She was also reported to have had alopecia and thin hair since early childhood. Her neonatal and developmental histories were reported to have been unremarkable. Patient 3 is myopic and a hearing assessment revealed mild sensorineural hearing loss. She had no abnormal movements. Currently, she has learning disabilities with fair school performance; her IQ is 71, suggesting borderline intellectual disability. On physical examination, her weight and height were at the 25th centile and her head circumference was at the 5th centile. Tanner stage was 2; she had minimal breast budding and pubic hair. Patient 3 was noted to have a long face, frontal alopecia with sparse scalp hair and eyebrows, and partial syndactyly of the second and third fingers. She had a large hyperpigmented macule extending from the left mandibular area to the left pectoral area that was well circumscribed with irregular borders. As with the other patients, bone age was delayed by 3 years and no scoliosis was seen. Hormone studies showed normal growth hormone, prolactin, cortisol, LH, FSH, TSH, and T4 levels; however, estradiol was low at <37 pmol/l (reference range: Follicular: 88–418, Mid Cycle: 228–1960, Luteal: 294–1102). Her HbA1C level

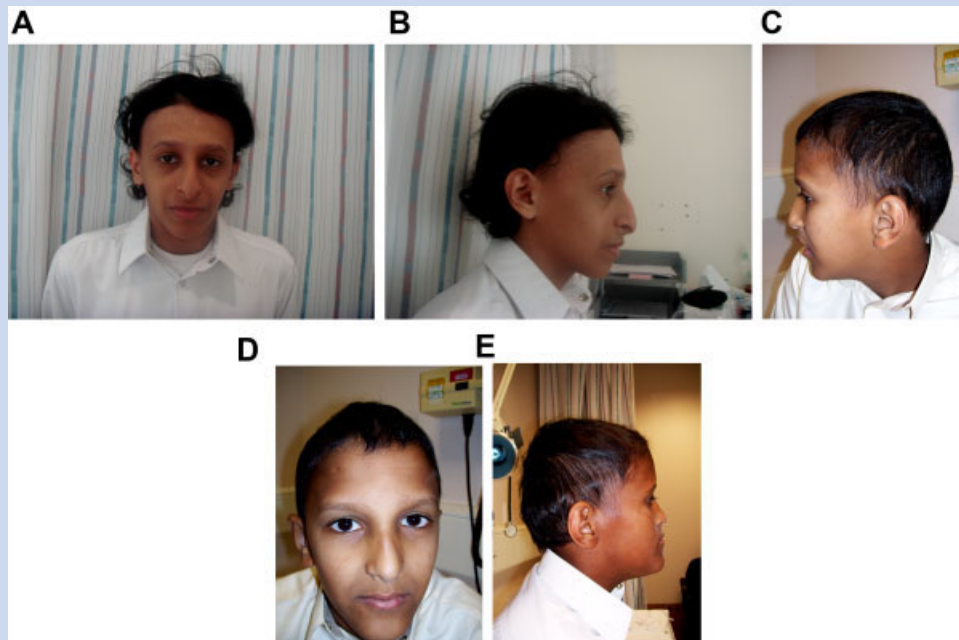


FIG. 3. Facial features and alopecia in three of our patients; (A,B) Patient 1, (C,D) Patient 5; (E) Patient 6. [Color figure can be seen in the online version of this article, available at [http://onlinelibrary.wiley.com/journal/10.1002/\(ISSN\)1552-4833](http://onlinelibrary.wiley.com/journal/10.1002/(ISSN)1552-4833)].

was 5.9 (reference range: 4.8–6) and IGF-1 was low at 32 (reference range: 187.9–400). Patient 3's pelvic MRI also revealed a hypoplastic uterus and non-visualized ovaries.

Family 2

The parents are healthy second cousins who have one affected daughter, three affected sons, four unaffected children, and a history of a first trimester miscarriage. Figure 2 illustrates the family pedigree. See Table I for a condensed look at the patients' symptoms, and Table III for the laboratory findings.

Patient 4 is a 19-year-old female who was born after an uneventful pregnancy and delivery. She presented at 14 years of age with primary amenorrhea and delayed puberty. She had partial alopecia and friable hair starting early in life. There was no history of abnormal movements. Her motor and cognitive development was appropriate, but she currently has learning disabilities, IQ: 71, suggestive of borderline intellectual disability. On examination, her weight and height were at the 25th centile her head circumference was at the 5th centile. Tanner stage was 2; she had minimal breast buds and no axillary or pubic hair. She was noted to have a long face, alopecia of the frontal and temporal regions with friable hair, and sparse eyebrows. There was no scoliosis. Chest and abdominal examination, as well as neurological examinations were normal. Hearing assessment showed mild sensorineural deafness, and an ophthalmological evaluation was normal. Endocrinology workup revealed a low estradiol level of <37 pmol/l, (reference range: Follicular: 88–418, Mid Cycle: 228–1960, Luteal: 294–1102) normal LH and FSH, and normal growth hormone and prolactin levels. She had a very low IGF-1 level of 15 (reference

range: 187.9–400), and an elevated HbA1C of 6.9 (reference range: 4.8–6). Transperineal ultrasound showed a small uterus and tiny ovaries, and, although further evaluation by MRI was recommended, the patient declined follow-up imaging.

Patient 5 is an 18-year-old male who presented at 15 years of age with delayed puberty, hyperactivity and learning disability, IQ: 68, suggestive of mild intellectual disability (Fig. 3). Antenatal and perinatal histories were unremarkable. He had normal early gross motor development and no history of abnormal movements. On examination, his height and weight were below the 5th centile. He was noted to have a long face with deep-set eyes, partial alopecia in the frontal and temporal regions, and sparse eyebrows and eyelashes. There was no facial, axillary or pubic hair. Both testes were small and Tanner stage was 1. Patient 5 had normal hearing, vision, cardiac, abdominal, neurological, and skeletal examinations. His hormone analysis revealed low normal LH and FSH levels and a low testosterone level of 2.03 nmol/l (reference range: 3.47–41.64). The IGF-1 level was also low at 67 ng/ml (reference range: 187.9–400).

Patient 6 is a 15-year-old male who was evaluated at 12 years of age for hyperactivity and poor school performance, IQ: 60, suggestive of mild intellectual disability (Fig. 3). He had a normal neonatal period, unremarkable early development and no history of abnormal movements. On examination, his height and weight were at the 25th centile. He was noted to have a long face with deep-set eyes, partial alopecia in the temporal and frontal regions, and sparse eyebrows and eyelashes. There was no axillary or pubic hair, both testes were small and Tanner stage was 1. Patient 6 also had normal hearing, vision, cardiac, abdominal, neurological, and skeletal examinations. His hormone analysis revealed low LH and FSH

TABLE I. Comparison of Clinical Features for WSS of in Our Patients

Ref	Age/sex	Alopecia	Hypogonadism	Mental delay	Diabetes	Deaf	CNS	Pelvic examination	MRI head	Ophthalmology	Comment
Family 1											
Patient 1	23/M	Yes	Yes	Yes	No	Yes	No	ND	N	Myopia	IQ: 75
Patient 2	20/F	Yes	Yes	Yes	No	Yes	No	Hypoplastic uterus and non-visualized ovaries.	N	Keratoconus	IQ: 78
Patient 3	17/F	Yes	Yes	Yes	No	Yes	No	Hypoplastic uterus and non-visualized ovaries.	ND	Myopia	IQ: 71
Family 2											
Patient 4	19/F	Yes	Yes	Yes	Yes	Yes	No	A small uterus and tiny ovaries	ND	N	IQ: 71
Patient 5	17/M	Yes	Yes	Yes	No	No	No		ND	N	IQ: 68
Patient 6	15/M	Yes	Yes	Yes	No	No	No		Diffusely increased periventricular white matter and centrum semiovale signal intensities on T2 images, suggestive of white matter hypomyelination	N	IQ: 60
Patient 7	8/M	Yes	Yes	Yes	No	No	No		ND	N	IQ: 66

levels and a low testosterone level of 1.85 nmol/l (reference range: 3.47–41.64). The IGF-1 level was also low at 64 ng/ml (reference range: 187.9–400). Brain MRI showed diffusely increased periventricular white matter and centrum semiovale signal intensities on T2 images, suggestive of white matter hypomyelination, but was otherwise unremarkable.

Patient 7 is an 8-year-old male who was evaluated at 6 years of age for hyperactivity and poor school performance, IQ: 66, suggestive of mild intellectual disability. He had a normal neonatal period, unremarkable early development and no history of abnormal movements. The family reported that he has learning disabilities. On examination, his height and weight were at the 5th centile. He was noted to have a long face with deep-set eyes, partial alopecia in the temporal region, friable hair, and sparse eyebrows. He had small testes and the Tanner stage was 1. The remainder of his physical examination was unremarkable, including his hearing and vision. Patient 7's hormonal studies showed low LH, testosterone and IGF-1.

See Table II for a synopsis of previously reported patients' symptoms, as well as Table IV for their corresponding laboratory findings.

GENETIC STUDIES

The four affected patients from Family 2 were subjected to genome-wide SNP analysis by Illumina 550K microarray and areas of homozygosity shared by all four were tabulated. The largest area of shared homozygosity was on chromosome 2, measured 6.9cM (6.0 Mb), and contained the *C2orf37* gene known to be associated with WSS. Given the phenotypic similarity of the affected individuals in this family to WSS, *C2orf37* was sequenced. Primer3 software was used to design sequencing primers. A homozygous one base pair deletion in exon 4 of *C2orf37* (c.436delC) was identified in all affected four individuals of Family 2. Subsequently, the patients from Family 1 were also identified to have the same *C2orf37* mutation.

Research protocols were approved by the participating institutions, and all the research procedures followed were in accordance with the ethical standards of the responsible national and institutional committees on human subject research.

DISCUSSION

We report on seven patients from two families with WSS and a homozygous mutation in the *C2orf37* gene. The constellation of clinical features described in these patients is relatively unique to WSS. These include delayed puberty, primary amenorrhea, frontal alopecia, and learning disabilities. The patients in the Family 1 also had sensorineural hearing loss and poor vision. Certain manifestations of WSS do not appear until later ages, and thus making the diagnosis in children particularly challenging. For example, none of the patients presented herein had evidence of diabetes mellitus or extrapyramidal symptoms. Though the natural history of WSS has not been completely elucidated, published cases suggest that diabetes and extrapyramidal symptoms usually do not appear until late teens or early adulthood [Al-Semari and Bohlega, 2007; Alazami et al., 2010]. The combination of hypogonadotropic hypogonadism

TABLE II. Comparison of Clinical Features for WSS in Previously Reported Cases

Ref	Age/sex	Alopecia	Hypogonadism	Mental delay	Diabetes	Deaf	CNS	Pelvic examination	MRI head	Ophthalmology	Comment
Crandall et al. [1973]											
Patient 1	21/M	Yes	Yes	Yes	NR	Yes					IQ:87
Patient 2	19/M	Yes	Yes	Yes	NR	Yes					IQ:97
Patient 3	18/M	Yes	Yes	Yes	NR	Yes					IQ:87
Al Awadi et al. [1985]											
Patient 1	18/F	Yes	Yes	NR	NR	NR		Ovaries, fallopian tubes absent			
Patient 2	16/F	Yes	Yes	NR	NR	NR		Streak ovaries, hypoplastic tubes			
Patient 3	22?M	Yes	Yes	NR	NR	NR		Azospemia, no germinal elements			
Devriendt et al. [1996]											
Patient 1	12/M	Yes	Yes	NR	NR	No	Dysarthria, Dystonia		White matter disease		
Patient 2	14/F	Yes	Yes	Yes		No					
Gül et al. [2000]											
Patient 1	32/M	Yes	Yes	Yes	Yes	Yes		NR			
Siti and Salem [1979]											
Patient 1	16/M	Yes	Yes	NR	NR	NR					
Patient 2	20/M	Yes	Yes	NR	NR	NR					
Patient 3	21/M	Yes	Yes	NR	NR	NR					
Oerter et al. [1992]											
Patient 1	24/F	Yes	Yes	Yes	Yes	Yes		Infantile uterus			
Patient 2	20/F	Yes	Yes	Yes	Yes	Yes		Infantile uterus			
Patient 3	13/M	Yes	Yes	Yes	Yes	Yes					
Patient 1	18/M	Yes	Yes	Yes	No	Yes					
Woodhouse and Sakati [1983]											
Patient 1	22/M	Yes	Yes	Yes	Yes	Yes					
Patient 2	17/M	Yes	Yes	Yes	Pre-diabetic						
Patient 3	21/F	Yes	Yes	Yes	Yes	Yes		Hypoplastic uterus, Streak ovaries			
Patient 4	16/F	Yes	Yes	Yes	Yes	Yes					
Patient 5	40/F	Yes	Yes	Yes	Yes	Yes					
Patient 6	47/M	Yes	Yes	Yes	Yes	Yes					
Susanne et al. [2008]											
Patient 1	36/M	Yes	Yes	Yes	Yes	Yes	Dystonia		White matter disease		Keratoconus
Patient 2	22/F	Yes	Yes	Yes	Yes	Yes	Dystonia-seizure				
Alazami et al. [2010]											
Patient 1	36/M	Yes	Yes	Yes	No	No	Dystonia		White matter changes		
Patient 2	41/F	Yes	Yes	Yes	Yes	Yes					
Patient 3	15/M	Yes	Yes	Yes	No	Yes					
Patient 4	12/F	Yes	Yes	No	No	No					
Patient 5	12/F	Yes	Yes	No	No	No					
Patient 6	58/M	Yes	Yes	Yes	Yes	Yes	Dystonia				
Patient 7	47/F	Yes	Yes	Yes	Yes	Yes	Dystonia				

TABLE III. Laboratory Findings in our Patients

Ref	FSH	LH	GH	IGF-1	T4	PRL	Cortisone	Testosterone	Estrogen	Insulin
Family 1										
Patient 1	N	N	N	Low	N	N	N	N (after treatment)		N
Patient 2	N	N	N	Low	N	N	N		Low	N
Patient 3	N	N	N	Low	N	N	N		Low	N
Family 2										
Patient 4	N	N	N	Low	N	N	N		Low	N
Patient 5	Low N	Low N	N	Low	N	N	N	Low		N
Patient 6	Low	Low	N	Low	N	N	N	Low		N
Patient 7	Low	Low	N	Low	N	N	N	Low		N

and partial alopecia should raise suspicion for WSS, but hypogonadism is usually not apparent until puberty and alopecia can be mild and become more noticeable with age [Woodhouse and Sakati, 1983]. These factors made arriving at the diagnosis of WSS initially difficult when these patients first presented.

The mutation identified in our patients, a base pair deletion in exon 4 of *C2orf37*, has been reported in a total of seven families from Saudi Arabia [Alazami et al., 2008], thus likely representing a founder mutation in this region. Al-Semari and Bohlega presented 26 patients with WSS from 12 families in Saudi Arabia [Al-Semari

and Bohlega, 2007]. Although these families seem to share the same founder mutation and comprise a fairly genetically homogeneous population, our patients show that variability in clinical presentation exists. For example, diabetes mellitus is noted as early as 17 years of age, but in some patients may not be present after 30 years of age. Dystonia is also reported as early as 17 years, but a 43-year-old patient is reported to have no dystonia. LH and FSH are often normal, but both high and low levels have been reported. Such variable expression might suggest the presence of disease modifying factors.

TABLE IV. Laboratory Findings in Previously Reported Cases of WSS

Ref	FSH	LH	GH	IGF-1	T4	PRL	Cortisone	Testosterone	Estrogen	Insulin
Crandall et al. [1973]										
Patient 1	N	Low	Low	NR	NR	NR		Very low		NR
Patient 2	N	Low	Low	NR	NR	NR		Low		NR
Patient 3	N	N	N	NR	NR	NR		N		NR
Al Awadi et al. [1985]										
Patient 1	High	High	NR	NR	N	NR	N		NR	NR
Patient 2	High	High	NR	NR	NR	NR	NR		NR	NR
Patient 3	High	N								
Devriendt et al. [1996]										
Patient 1	N	N	NR	NR	NR		Low normal	Low		
Patient 2	High	High	NR	NR	NR	NR			NR	
Gül et al. [2000]										
Patient 1	N	N	NR	NR	NR	NR	Low	NR	NR	
Slti and Salem [1979]										
Patient 1	Low	Low	N	NR	NR	N		very low		NR
Patient 2	Low	Low	N	NR	NR	N		very low		NR
Patient 3	High	Low	N	NR	NR	N		very low		NR
Oerter et al. [1992]										
Patient 1	N	N	Low	NR	N	N			NR	
Patient 2	N	N	Low	NR	N	N			NR	
Patient 3	N	N	Low	NR	N	N		NR		
Patient 1	N	N	Low	NR	N	N		NR		
Woodhouse and Sakati [1983]										
Patient 1	N	N	NR	NR	NR	Slightly high	Low		N	
Patient 2	N	N	NR	NR	NR	N		Very low		
Patient 3	High	High	NR	NR	NR	N		Very low		
Patient 4	High	High	NR	NR	NR	N		Very low		
Patient 5	N	N	NR	NR	NR	N			N	

Founder effect is a loss of genetic diversity in an isolated population wherein a particular mutation is thought to be the sole cause of a certain trait or disease [Aldahmesh et al., 2009]. The high incidence of consanguineous unions in this region increases allelic heterogeneity for such a rare disorder. This, according to Aldahmesh et al. [2009] goes counter to the founder effect, and consequently, explains the relatively low genetic variation. Additional mutations in *C2orf37* have been reported from other ethnicities [Steindl et al., 2010; Alazami et al., 2010]. This suggests that mutations in *C2orf37* are responsible for WSS in other ethnicities.

In conclusion, it is important to consider WSS in patients presenting with hypogonadism, frontal alopecia and learning disabilities, even in the absence of diabetes and extrapyramidal manifestations. In WSS, cognitive dysfunction is usually present early in life, but other manifestations such as diabetes and extrapyramidal symptoms might not appear until adolescence or early adulthood, and so making the diagnosis early can be difficult. Mutation analysis of *C2orf37* can be used to confirm the diagnosis of WSS once suspicion is raised. Endogamy and high consanguinity contribute to the clustering of such rare autosomal recessive syndromes in the Arab world and, based on this and previous reports; it appears that WSS is probably not as rare among the Arabs as previously thought.

ACKNOWLEDGMENTS

The authors would like to thank all patients and their families for their excellent collaboration. Special thanks go to Dr. Ganeshwaran H. Mochida, Dr. Wen-Hann Tan, Jennifer N. Partlow, and Basel A. Teebi for editing the manuscript.

REFERENCES

- Al-Awadi SA, Farag TI, Teebi AS, Naguib K, el-Khalifa MY, Kelani Y, Al-Ansari A, Schimke RN. 1985. Primary hypogonadism and partial alopecia in three sibs with müllerian hypoplasia in the affected females. *Am J Med Genet* 22:619–622.
- Alazami AM, Al-Saif A, Al-Semari A, Bohlega S, Zlitni S, Alzahrani F, Bavi P, Kaya N, Colak D, Khalak H, Baltus A, Peterlin B, Danda S, Bhatia KP, Schneider SA, Sakati N, Walsh CA, Al-Mohanna F, Meyer B, Alkuraya FS. 2008. Mutations in *C2orf37*, encoding a nucleolar protein, cause hypogonadism, alopecia, diabetes mellitus, mental retardation, and extrapyramidal syndrome. *Am J Hum Genet* 83:684–691.
- Alazami AM, Schneider SA, Bonneau D, Pasquier L, Carecchio M, Kojovic M, Steindl K, de Kerdanet M, Nezarati MM, Bhatia KP, Degos B, Goh E, Alkuraya FS. 2010. *C2orf37* mutational spectrum in Woodhouse–Sakati syndrome patients. *Clin Genet* 78:585–590.
- Aldahmesh MA, Abu-Safieh L, Khan AO, Al-Hassnan ZN, Shaheen R, Rajab M, Monies D, Meyer BF, Alkuraya FS. 2009. Allelic heterogeneity in inbred populations: The Saudi experience with Alström syndrome as an illustrative example. *Am J Med Genet Part A* 149A:662–665.
- Al-Semari A, Bohlega S. 2007. Autosomal-recessive syndrome with alopecia, hypogonadism, progressive extra-pyramidal disorder, white matter disease, sensory neural deafness, diabetes mellitus, and low IGF1. *Am J Med Genet Part A* 143A:149–160.
- Crandall BF, Samec L, Sparkes RS, Wright SW. 1973. A familial syndrome of deafness, alopecia, and hypogonadism. *J Pediatr* 82:461–465.
- Devriendt K, Legius E, Fryns JP. 1996. Progressive extrapyramidal disorder with primary hypogonadism and alopecia in sibs: A new syndrome? *Am J Med Genet* 62:54–57.
- Gül D, Ozata M, Mergen H, Odabaşı Z, Mergen M. 2000. Woodhouse and Sakati syndrome (OMIM 241080): Report of a new patient. *Clin Dysmorph* 9:123–125.
- Koshy G, Danda S, Thomas N, Mathews V, Viswanathan V. 2008. Three siblings with Woodhouse–Sakati syndrome in an Indian family. *Clin Dysmorph* 17:57–60.
- Medica I, Sepčić J, Peterlin B. 2007. Woodhouse–Sakati syndrome: Case report and symptoms review. *Genet Counsel* 18:227–231.
- Oerter KE, Friedman TC, Anderson HC, Cassorla FG. 1992. Familial syndrome of endocrine and neuroectodermal abnormalities. *Am J Med Genet* 1;44(4): 487–491.
- Rachmiel M, Bistrizter T, Hershkoviz E, Khahil A, Epstein O, Parvari R. 2011. Woodhouse–Sakati Syndrome in an Israeli-Arab family presenting with youth-onset diabetes mellitus and delayed puberty. *Horm Res Paediatr* 75:362–366.
- Schneider SA, Bhatia KP. 2008. Dystonia in the Woodhouse–Sakati syndrome: A new family and literature review. *Mov Disord* 23:592–596.
- Slti IS, Salem Z. 1979. Familial hypogonadotropic hypogonadism with alopecia. *Can Med Assoc J* 18;121: 428–430, 433–434.
- Steindl K, Alazami A, Bhatia K, Wuerfel J, Petersen D, Cartolari R, Neri G, Klein C, Mongiardo B, Alkuraya F, Schneider S. 2010. A novel *C2orf37* mutation causes the first Italian cases of Woodhouse Sakati syndrome. *Clin Genet* 78:594–597.
- Woodhouse NJ, Sakati NA. 1983. A syndrome of hypogonadism, alopecia, diabetes mellitus, mental retardation, deafness, and ECG abnormalities. *J Med Genet* 20:216–219.